

A case of successful treatment of Fordyce spots with a single insulated microneedle radiofrequency device

Ga Ram Ahn¹  | Su Jung Park¹  | Chang Kyun Lee² | Beom Joon Kim¹ 

¹Department of Dermatology, Chung-Ang University Hospital, Seoul, South Korea

²Department of Dermatology, Chungdam Gwoonsesang Dr. G Dermatology Clinic, Seoul, South Korea

Correspondence

Beom Joon Kim, Department of Dermatology, Chung-Ang University Hospital, 102 Heukseok-ro, Dongjak-gu, Seoul 06973, South Korea.
Email: beomjoon74@gmail.com

Abstract

Fordyce spots are ectopic sebaceous glands which typically present as asymptomatic, multiple whitish, or yellowish 1–3-mm sized papules on the lips. Several therapeutic approaches have been proposed such as laser, electrical or chemical ablation, and micropunch excision. However, these modalities pose the risk of scarring from inevitable surface damage. In this report, we present a case of Fordyce spots which was successfully treated with intralesional electrocoagulation using a proximally insulated microneedle and monopolar radiofrequency device, resulting in marked cosmetic improvements without surface damage.

KEYWORDS

Fordyce spots, insulated microneedle, monopolar radiofrequency

1 | INTRODUCTION

As the need for improved appearances through cosmetic surgery becomes more complex and diversified, there have recently been instances of some patients requesting the removal of Fordyce spots on their lips. Since the Fordyce spots are located on the very center of the face, the ideal treatment goal should be achieved without surface damage. Although various therapeutic modalities have been reported, such as laser ablation (Ocampo-Candiani, Villarreal-Rodriguez, Quinones-Fernandez, Herz-Ruelas, & Ruiz-Esparza, 2003), direct electrocauterization and curettage (Chern & Arpey, 2008), and chemical ablation with bichloroacetic acid (Plotner & Brodell, 2008), these treatment options inevitably leave surface damage. Hence, we report a case of Fordyce spots which was successfully treated through intralesional electrocoagulation with a proximally insulated microneedle, sparing epidermal damage.

2 | CASE REPORT

A 32-year-old male patient visited our clinic complaining of multiple small granules on his lips. The granules were flesh-colored and partly confluent, thereby causing cosmetic problems on his lips (Figure 1a). To remove the lesions without surface damage, intralesional electrocoagulation with a

proximally insulated single microneedle was selected as the treatment modality. To reduce pain during the procedure, tumescent local anesthesia was performed with buffered lidocaine-epinephrine solution. For the intralesional electrocoagulation, a 1-MHz monopolar radiofrequency (RF) device (AGNES[®], AGNES Medical, Inc., Seongnam, South Korea) with a proximally insulated microneedle (S-type, AGNES Medical, Inc.) (Figure 2) was used. To enhance the accuracy, the patient's lips were stretched horizontally during the treatment using the fingers (Figure 1b). Then, one to two shots of RF energy (10 W, 100 ms) were transmitted intralesionally into each granule through the proximally insulated microneedle. After the procedure, mupirocin ointment was applied once without further dressing. The patient tolerated the procedure well and reported no significant adverse events except for mild crusting, which lasted only until the next day. On the follow-up visit 3 months after the procedure, the size and number of granules were clearly decreased and the patient was satisfied with the cosmetic result (Figure 1c,d).

3 | DISCUSSION

Fordyce spots characteristically present as asymptomatic, usually multiple, yellow to yellow-white papules. These granules are typically no more than 1–2 mm in diameter and often occur on the vermilion portion of the upper lip. In the view of histopathology, Fordyce spots are

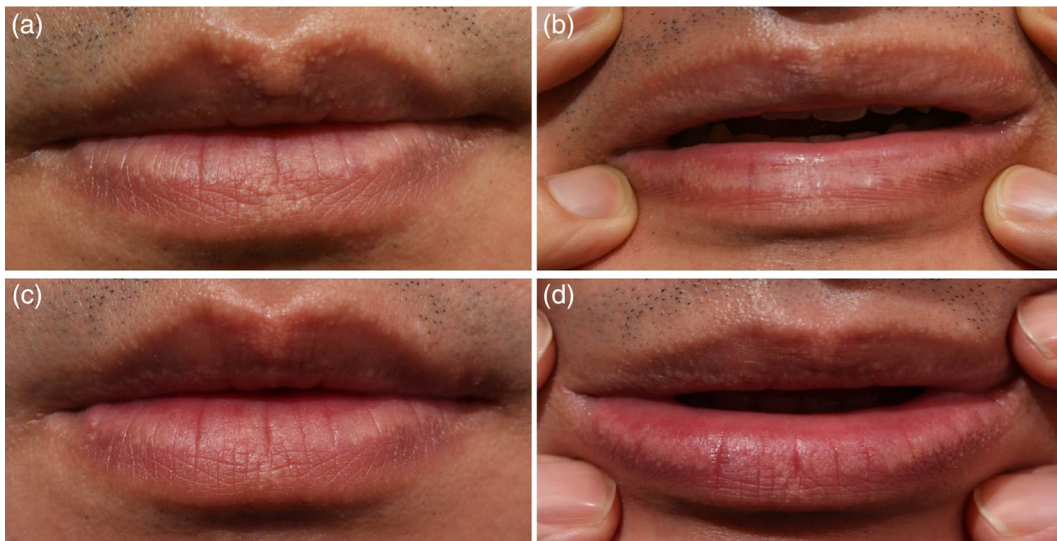

FIGURE 1 (a) Multiple flesh-colored papules on the lips, before treatment. (b) The lips are laterally stretched to enhance accuracy. (c,d) The size and number of granules are markedly decreased 3 months after treatment




FIGURE 2 Magnified image of the microneedle used in this case. Note the proximally insulated part on the microneedle

regarded as free sebaceous glands because each lesion consists of a group of small but mature sebaceous lobules situated around a small sebaceous duct leading to the surface epithelium (Daley, 1993).

Despite the benign nature of Fordyce spots, there have been some demands for removal for cosmetic reasons. Considering that Fordyce spots are not related to life-threatening conditions and are located on the center of the face and result only in cosmetic

disturbances, destruction of the dermal microcomponent (free sebaceous glands) with minimal invasiveness would be essential to achieve fine treatment outcomes. However, none of the conventional therapeutic options met the ideal conditions.

Oral isotretinoin can be used for the treatment of Fordyce spots through its sebum-suppressive effect. However, the lesions recur 1 month (Mutizwa & Berk, 2014) to 9 weeks (Monk, 1993) after discontinuation because drug-induced suppression does not lead to permanent regression of the causative sebaceous glands. Surgical excision with micropunch has also been attempted in the genital regions (Pallua & Stromps, 2013). However, considering scar formation, it should be the last option for lesions on the lips. Similarly, the use of curettage with electrocauterization leaves scars and causes changes in skin texture (Chern & Arpey, 2008). Until recently, carbon dioxide (CO₂) laser ablation (Ocampo-Candiani et al., 2003) has been widely used for the treatment of Fordyce spots. However, the laser beam must vaporize the epidermis to reach the deeper target tissue in the dermis. Consequentially, the procedure may result in considerable downtime (7–10 days) and some alterations of surface texture after wound healing.

Intralesional electrocoagulation can be a good alternative to overcoming these difficulties. The S-type microneedle, which was used in this case, has insulation on its proximal portion (Figure 2), allowing the RF energy to bypass the epidermis and destruct the target dermal microcomponent exclusively. This feature seems to contribute to the short downtime in this case (0–1 day) compared to the ordinary direct RF cautery and curettage (crusting for 1 week) (Chern & Arpey, 2008) or CO₂ laser ablation (710 days) (Ocampo-Candiani et al., 2003). Moreover, the S-type microneedle has a very short insulated part (0.2 mm) that enables RF energy to coagulate the free sebaceous glands of Fordyce spots that are usually located in the superficial dermis. The T-shaped shoulder of the microneedle, which acts as a stopper, provides uniform depth across sessions, regardless of the physician.

As in this case, many authors experienced fine treatment outcomes with intralesional electrocoagulation for various indications. The technique can be utilized for selective destruction of intradermal target tissues without surface injury: sebaceous glands in acne (Kwon et al., 2017; Lee, Kim, Kim, Ahn, & Aso, 2012) and facial seborrhea (Kobayashi & Tamada, 2007), eccrine glands in axillary bromhidrosis and hyperhidrosis (Kobayashi, 1988), dilated vessels in facial telangiectasia (Kobayashi, 1986), dermal tumors in trichoepithelioma (Hong, Seok, Kim, Jang, & Kim, 2018), syringoma (Hong et al., 2010), and lipoma (Hong, Jung, Li, & Kim, 2018).

Through our experience, we demonstrated that Fordyce spots can also be a good candidate for intralesional electrocoagulation with a proximally insulated single microneedle. To confirm the detailed efficacy and safety, larger case studies are expected.

CONFLICT OF INTEREST

The authors declare no potential conflict of interest.

ORCID

Ga Ram Ahn  <https://orcid.org/0000-0002-5696-4699>

Su Jung Park  <https://orcid.org/0000-0001-9314-6401>

Beom Joon Kim  <https://orcid.org/0000-0003-2320-7621>

REFERENCES

- Chern, P. L., & Arpey, C. J. (2008). Fordyce spots of the lip responding to electrodesiccation and curettage. *Dermatologic Surgery*, 34(7), 960–962.
- Daley, T. (1993). Pathology of intraoral sebaceous glands. *Journal of Oral Pathology and Medicine*, 22(6), 241–245.
- Hong, J. Y., Jung, G. J., Li, K., & Kim, B. J. (2018). Noninvasive size reduction of lipoma with an insulated monopolar radiofrequency microneedle device. *Dermatologic Therapy*, 31(4), e12608.
- Hong, J. Y., Seok, J., Kim, J. M., Jang, Y. J., & Kim, B. J. (2018). Successful treatment of trichoepithelioma with a novel insulated, monopolar, radiofrequency microneedle device. *Clinical and Experimental Dermatology*, 43(1), 108–109.
- Hong, S. K., Lee, H. J., Cho, S. H., Seo, J. K., Lee, D., & Sung, H. S. (2010). Syringomas treated by intralesional insulated needles without epidermal damage. *Annals of Dermatology*, 22(3), 367–369.
- Kobayashi, T. (1986). Electrosurgery using insulated needles: Treatment of telangiectasias. *The Journal of Dermatologic Surgery and Oncology*, 12(9), 936–942.
- Kobayashi, T. (1988). Electrosurgery using insulated needles: Treatment of axillary bromhidrosis and hyperhidrosis. *The Journal of Dermatologic Surgery and Oncology*, 14(7), 749–752.
- Kobayashi, T., & Tamada, S. (2007). Selective electrothermolysis of the sebaceous glands: Treatment of facial seborrhea. *Dermatologic Surgery*, 33(2), 169–177.
- Kwon, T. R., Choi, E. J., Oh, C. T., Bak, D. H., Im, S. I., Ko, E. J., ... Kim, B. J. (2017). Targeting of sebaceous glands to treat acne by micro-insulated needles with radio frequency in a rabbit ear model. *Lasers in Surgery and Medicine*, 49(4), 395–401.
- Lee, J. W., Kim, B. J., Kim, M. N., Ahn, G. Y., & Aso, H. (2012). Selective sebaceous gland electrothermolysis as a treatment for acne: A prospective pilot study. *International Journal of Dermatology*, 51(3), 339–344.
- Monk, B. E. (1993). Fordyce spots responding to isotretinoin therapy. *British Journal of Dermatology*, 129(3), 355.
- Mutizwa, M. M., & Berk, D. R. (2014). Dichotomous long-term response to isotretinoin in two patients with Fordyce spots. *Pediatric Dermatology*, 31(1), 73–75.
- Ocampo-Candiani, J., Villarreal-Rodriguez, A., Quinones-Fernandez, A. G., Herz-Ruelas, M. E., & Ruiz-Esparza, J. (2003). Treatment of Fordyce spots with CO2 laser. *Dermatologic Surgery*, 29(8), 869–871.
- Pallua, N., & Stromps, J. P. (2013). Micro-punch technique for treatment of Fordyce spots: A surgical approach for an unpleasant condition of the male genital. *Journal of Plastic, Reconstructive and Aesthetic Surgery*, 66(1), e8–e11.
- Plotner, A. N., & Brodell, R. T. (2008). Treatment of Fordyce spots with bichloroacetic acid. *Dermatologic Surgery*, 34(3), 397–399.

How to cite this article: Ahn GR, Park SJ, Lee CK, Kim BJ. A case of successful treatment of Fordyce spots with a single insulated microneedle radiofrequency device. *Dermatologic Therapy*. 2019:e13026. <https://doi.org/10.1111/dth.13026>