

Efficacy and Safety of the Micro-insulated Needle Radiofrequency Device for Reduction of Submental Fat

Bo Ri Kim, MD, PhD,* Minjae Kim, MD,*† Jee Woo Kim, MD,*† Jung-Won Shin, MD, PhD,*† Jung-Im Na, MD, PhD,*† and Chang-Hun Huh, MD, PhD*†

BACKGROUND Recently, it has been reported that a micro-insulated needle radiofrequency (RF) system is effective at achieving subcutaneous fat reduction; however, no study has yet applied this technique to reduce submental fat.

OBJECTIVE To evaluate the efficacy and safety of a fractional RF device with a micro-insulated needle to reduce submental fat.

MATERIALS AND METHODS In this prospective, single-blinded, pre–post comparative study, 24 adults with excess submental fat were treated once using a micro-insulated needle RF device. Outcomes included efficacy (submental fat rating by an independent investigator, fat volume quantified with a 3-dimensional camera, and patient satisfaction), assessed 1 and 2 months after the procedure, and safety (adverse events), assessed throughout the study.

RESULTS The patients' Physician-Assisted Submental Fat Rating Scale score significantly decreased after 1 month and further decreased after 2 months. The average volume of submental fat was significantly decreased after 2 months (20.44 ± 5.53 cc to 16.41 ± 4.58 cc, $p < .001$). Patient satisfaction was high. Transient and mild local skin reactions without long-term sequelae were observed in 4 patients.

CONCLUSION The micro-insulated needle RF device is beneficial for the reduction of submental fat and has tolerable safety profiles.

Trial registration ClinicalTrials.gov Identifier: NCT05517824.

Excess submental fat, known as double chin or submental fullness, is a common cosmetic concern in both men and women. Because a well-contoured jawline and a sharp cervicomental angle give a perception of beauty and youth, there is a strong desire among people to reduce submental fat to allow jawline rejuvenation.¹ The etiology of excess submental fat is related to patients' weight gain and the aging process, as skin laxity increases and the submental fat pad descends and protrudes due to the pulling of gravity.^{2,3} However, submental fat is often difficult to reduce, regardless of diet and exercise. Therefore, various surgical and nonsurgical procedures have been developed to remove excess fat in the submental area.

“Traditionally, surgical liposuction is the most effective gold standard treatment for submental fat reduction, but like all surgery has limitations, such as ecchymosis and postoperative discomfort.”⁴ To overcome these weaknesses, minimally invasive or noninvasive fat

reduction techniques have recently emerged and are gaining popularity in patients who cannot undergo liposuction surgery for medical reasons, including anticoagulant therapy, or who simply prefer more conservative treatments.^{3,5}

Radiofrequency (RF) devices induce noninvasive fat reduction by generating heat energy through the high-impedance tissues of subcutaneous fat, causing disintegration of adipocytes and triggering the apoptosis of subcutaneous fat cells.⁶ In addition, the thermal effect of RF is known to cause dermal collagen contraction and neocollagenesis, contributing to skin tightening and rejuvenation.⁷ A fractional RF using microneedles, which allows focused RF energy to be delivered to deeper tissues with minimal superficial involvement, has shown clinical efficacy in the treatment of wrinkles, acne vulgaris, and scars.^{7,8} More recently, a study demonstrated that a fractional RF device with micro-insulated needles (AGNES; Gowoonsesang Cosmetics Co., Seongnam, Gyeonggi, Korea) was effective in reducing lower eyelid fat bulging without inducing epidermal injury.⁹ In this study, the authors aimed to evaluate the efficacy and safety of the micro-insulated needle RF device for the reduction of submental fat to extend its indications.

Methods

Study Design and Population

This prospective, single-center, pre–post comparative study included 24 volunteers with excess submental fat. The study

From the *Department of Dermatology, Seoul National University Bundang Hospital, Seongnam; and †Department of Dermatology, Seoul National University College of Medicine, Seoul, Korea

This study was supported by Agnes Medical Co., Ltd.

The authors have indicated no significant interest with commercial supporters.

Address correspondence and reprint requests to: Chang-Hun Huh, MD, PhD, Department of Dermatology, Seoul National University Bundang Hospital, 82 Gumi-Ro 173 Beon-Gil, Seongnam, Gyeonggi 13620, Korea, or e-mail: chhuh@snu.ac.kr

Supplemental digital content is available for this article. Direct URL citations appear in the printed text and are provided in the HTML and PDF versions of this article on the journal's Web site (www.dermatologicsurgery.org).

<http://dx.doi.org/10.1097/DSS.00000000000003723>

protocol was approved by the institutional review board (IRB number: B-2012-655-001), and the study was conducted in accordance with the Declaration of Helsinki. Informed consent was obtained from all patients before participation. The authors followed the Transparent Reporting of Evaluations With Nonrandomized Designs reporting guideline.

Inclusion criteria were adults aged 20 years and older with excess submental fat on a grade of 1~4, as assessed by the Physician-Assisted Submental Fat Rating Scale (PA-SMFRS).¹⁰ The exclusion criteria were as follows: mental impairment, infectious disease, history of keloid development, pregnancy, pacemaker, the use of anticoagulants, and undergoing a face-lift procedure within the previous 6 months.

Treatment Protocol

A microneedle monopolar RF device with a frequency of 1 MHz was used to treat excess submental fat. The needle tip consisted of 3 microneedles, each of which was 4 mm in length, with an insulated proximal 2 mm and a non-insulated distal 2 mm (Figure 1A). Proximal insulation allowed the delivery of more heat to deeper skin tissues without thermal damage to the epidermis, and the shoulders of the needle prevented microneedles from being inserted more than 4 mm deep to avoid deep tissue injuries.

The patients underwent 1 treatment session. Before treatment, in a sitting position, the patient's chin was lowered as much as possible to maximize submental fat bulging, and the operators (C.-H.H and B.R.K) marked the treatment area with lateral borders approximately 3 cm inward from both the sternocleidomastoid muscles (Figure 1B). A topical anesthetic cream (EMLA) containing 2.5% lidocaine and 2.5% prilocaine was applied to the treatment area occluded for 30 minutes, and local anesthesia with 1% lidocaine and 1:100,000 epinephrine was additionally injected only on the outside of the treatment area along the marking line immediately before the procedure to minimize the impact on the treatment area. The operators inserted the needle of the RF device into the treatment area at a 90° angle while pinching the submental skin with the thumb and index finger of their nondominant hands to cause it to protrude. When the needle was inserted to a maximum depth of 4 mm, the treatment was performed with an exposure time of 400 ms and a power of 11 W (4.4 J per shot), and the insertion sites of the needle were approximately 3 mm apart from one another. To avoid possible damage to the marginal mandibular nerve, the 1.0-cm space below the mandibular border where the nerve is located was spared from treatment. A new needle tip was placed every 100 shots during the procedure. After treatment, the treated areas were gently compressed and cooled with ice packs for 20 minutes, and topical mupirocin ointment was applied.

Evaluation Measures

The evaluation was conducted at baseline, before treatment, and at 1 and 2 months after treatment. Standardized clinical

photographs of the frontal and profile views (45° and 90°) of the patients were obtained using identical digital camera settings and lighting conditions at each visit. The primary outcome measures included changes in PA-SMFRS assessed by a single dermatologist (J.W.S) using clinical photographs. The PA-SMFRS is a validated evaluation method

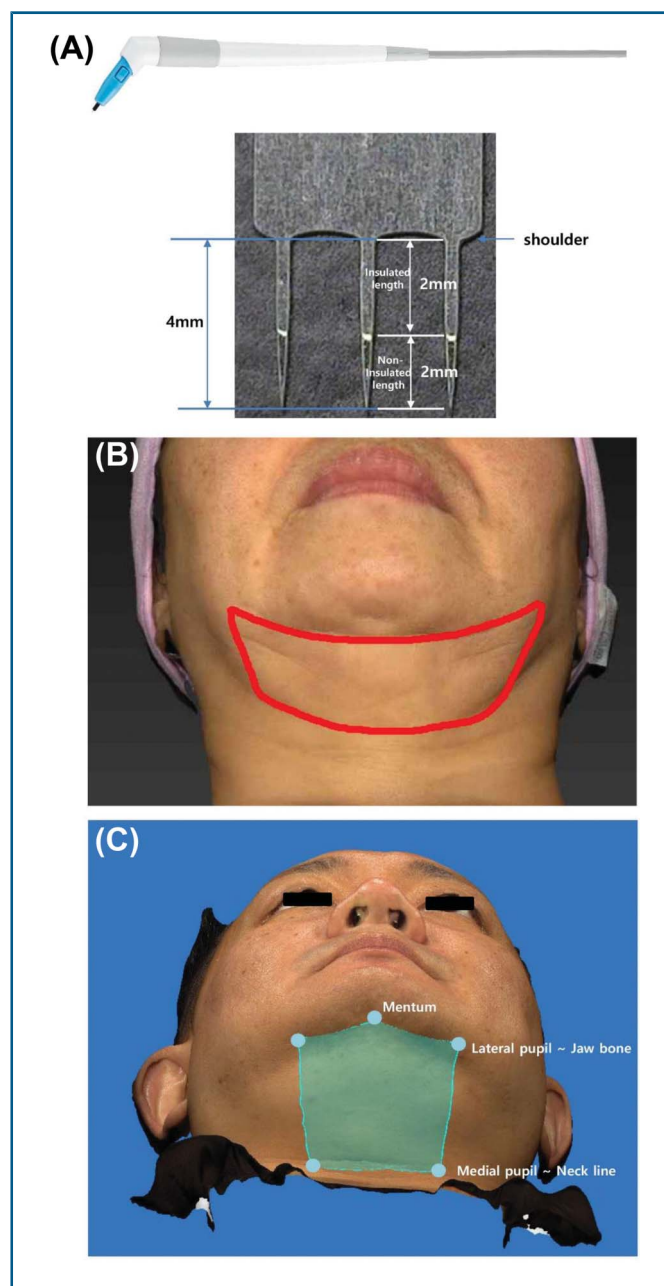


Figure 1. (A) The micro-insulated needle tip of the monopolar radiofrequency device. A tip with 3 microneedles 4 mm in length, with 2 mm of proximal insulation. (B) Area of the procedure under the chin. (C) Three-dimensional photographs obtained by Vectra 3D and landmarks required for analysis. An arbitrary reference plane connecting 5 points was used as the range for submental fat volume measurement, including 2 points where the right and the left lateral pupillary lines met at each jaw bone, 2 points where the right and the left medial pupillary lines met at each neck line, and 1 point at the mentum.

that grades the severity of submental fat from 0 (nothing) to 4 (very severe).

The secondary outcomes comprised the submental fat volume analyzed by 3-dimensional (3D) photogrammetry and the patient's subjective satisfaction with the improvement in submental fat. To objectively evaluate the change in submental fat volume, 3D images of each patient's submental area were obtained with a Vectra 3D H1-270 (CANFIELD, Parsippany, NJ) at baseline and 1 and 2 months after the treatment, and analyzed with dedicated software. The Vectra imaging system has been previously validated as a tool for capturing accurate and reproducible stereophotogrammetric images.¹¹ To measure the extent of submental fat bulging, the authors determined an arbitrary reference plane that linked 5 points: 2 points where the right and left lateral pupillary lines met at each jaw bone, 2 points where the right and left medial pupillary lines met at each neck line, and 1 point at the mentum (Figure 1C). The patient's satisfaction score for reduction of submental fat was evaluated from 0 (not satisfied) to 10 (most satisfied) at 1 and 2 months after treatment, when compared with before treatment using a visual analog scale. Furthermore, the patients were asked to report any adverse effects at any time during or after treatment. The investigators also checked for adverse effects during each follow-up visit.

Statistical Analysis

A sample size of 24 patients (24 pairs) is sufficient to detect a clinically important difference of 1.0 between pre-post changes in reducing mean PA-SMFRS, assuming a SD of 1.5 using a 2-tailed *t*-test with 80% power and a 5% level of significance.¹² The initial estimate of sample size included an assumption of a dropout rate of 10%.

Each measurement at the follow-up visit was compared with the baseline value using paired *t*-tests. The results are expressed as the mean \pm SD, and a *p*-value $<$.05 was considered statistically significant. IBM SPSS version 20 (IBM Corp., Armonk, NY) was used to analyze all data.

Results

Subject Characteristics and Shot Numbers

All the 24 patients enrolled in the study completed the treatment protocol and attended all follow-up visits (See Supplemental Digital Content, <http://links.lww.com/DSS/B218>). Their mean age was 40.13 ± 10.57 years (range 25–63 years), and women accounted for 62.5% of the study population. The average shot number of a single treatment was 394.5 ± 78.06 (range 196–516), and the average total energy per treatment was 1735.8 ± 343.45 J (range 862.4–2270.4 J).

PA-SMFRS

The mean PA-SMFRS scores showed a significant reduction at 1 and 2 months after treatment compared with before treatment. The mean PA-SMFRS score showed a statistically significant decrease to 2.46 ± 0.93 ($p < .001$) and 1.92

± 0.93 ($p < .001$) at 1 and 2 months after treatment, respectively, compared with the baseline score of 3.04 ± 0.81 (Figure 2A).

Submental Fat Volume

The mean submental fat volume (cc) at baseline and at 1 and 2 months after treatment was 20.44 ± 5.53 , 18.57 ± 4.11 , and 16.41 ± 4.58 , respectively (Figure 2B). The submental fat volume showed a marginally significant decrease at the 1-month follow-up (9.15% reduction, $p = .053$) and a significant decrease at the 2-month follow-up (19.72% reduction, $p < .001$) compared with the baseline values. Figure 3 shows the clinical photographs of 2 representative cases with excess submental fat that presented a marked improvement up to 2 months after a single treatment.

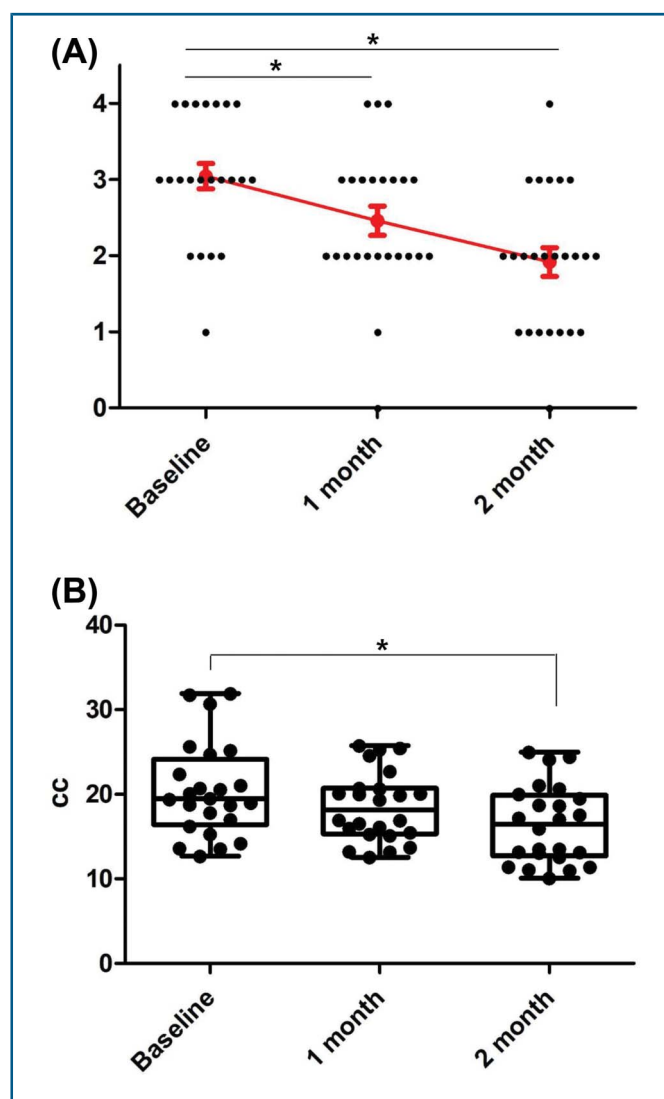


Figure 2. (A) Changes in Physician-Assisted Submental Fat Rating Scale (PA-SMFRS). (B) Changes in submental fat volume quantified by 3D image analysis. * $p < .05$ compared with baseline.

Patient Satisfaction and Adverse Events

The average patient satisfaction scores for reduction of submental fat at 1 and 2 months of follow-up were 6.54 ± 1.82 and 8.04 ± 1.52 , respectively. All these values were greater than 5 (no change) and continued to increase until 2 months of follow-up.

Four adverse events were reported during the study, all of which were local transient complications (erythema and oozing, superficial bulla, and ulcers in 2, 1, and 1 patient, respectively) not extending beyond the treatment area. For an acceptable cosmetic outcome, the scar erythema of the healed ulcer needed 3 vascular laser treatments; the other 3 adverse events were rated as mild and resolved spontaneously without sequelae. There were no serious adverse events such as persistent scar or prolonged numbness.

Discussion

This study is the first to apply a micro-insulated needle RF device to reduce submental fat. The data of this study showed that a fractional RF device with micro-insulated needles significantly reduced submental fat compared with baseline. With only one treatment, the average severity grade of submental fat evaluated by an investigator significantly improved, and the patient's subjective satisfaction with the reduction of submental fat after treatment was also high. Furthermore, the authors confirmed that the

average volume of submental fat measured objectively using the 3D photogrammetry system decreased continuously by 9.15% and 19.72% at 1 and 2 months after treatment, respectively, compared with the baseline.

Submental fat accumulation is a cosmetically distressing problem, for which there have been recent advances in minimally invasive and noninvasive therapeutic options. These nonsurgical treatments include laser/RF-assisted lipolysis, cryolipolysis, chemical lipolysis, and RF or high-intensity focused ultrasound (HIFU)-assisted contouring and can easily target the preplatysmal fat pad superficial to the platysma muscle with percutaneous techniques.⁵ Because there are no clinically important vessels or nerves superficial to the platysma except for the marginal mandibular branch of the facial nerve, it is relatively safer to perform procedures in this region.³ However, even with minimally invasive procedures, inherent risks still exist, such as erythema, edema, bruising, ulcerations, and paresthesia at the treatment site.

Laser- and RF-assisted lipolysis has been developed to improve the side effects and recovery time of surgical liposuction and reduce the manual effort of surgeons. However, these techniques still require submental stab incisions of up to 2.4 mm to insert a fiber optic cannula or RF probe into the subdermal space.^{13,14} They also have the disadvantages of requiring 3 to 7 days of recovery due to swelling and bruising and carry a small risk of nodularity,

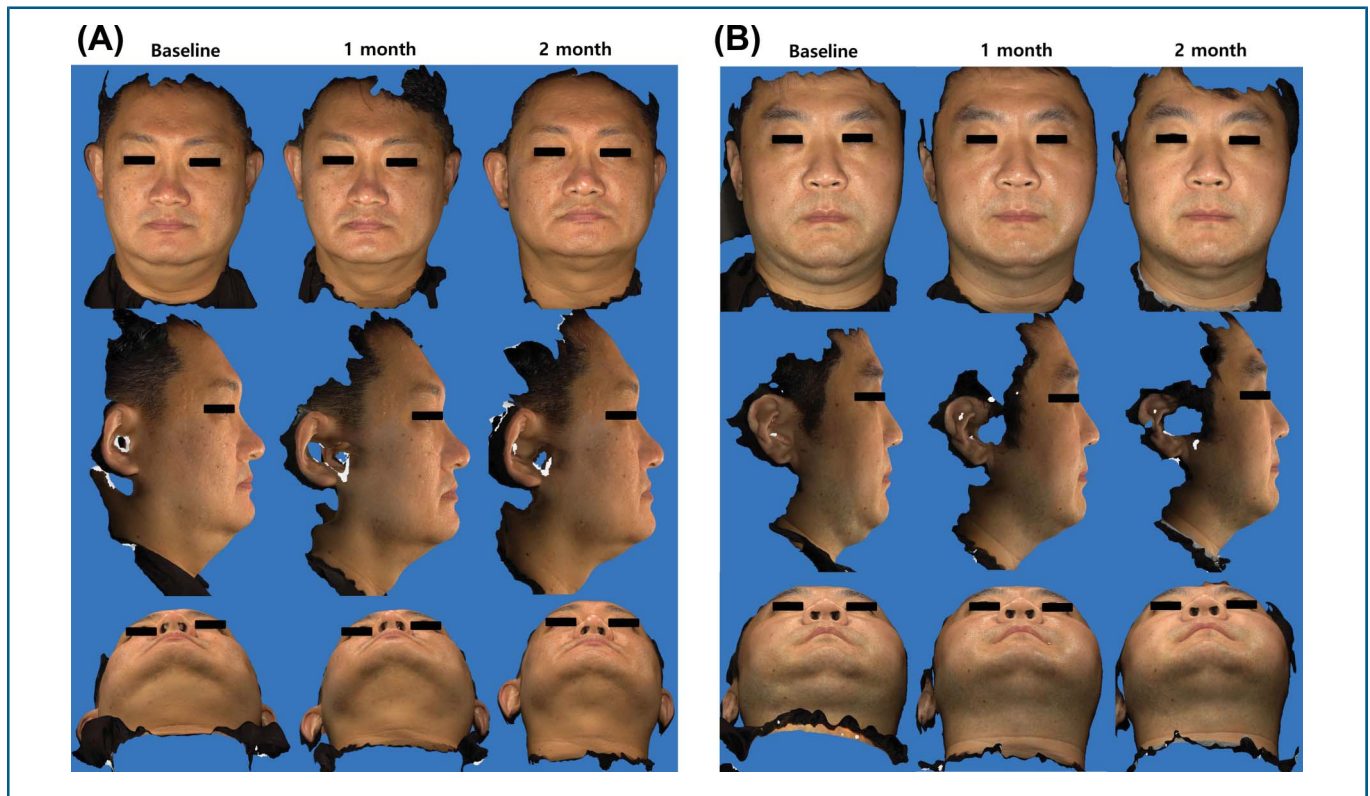


Figure 3. Clinical photographs of 2 representative cases with significant improvement in submental fat volume before and after treatment. (A) S12 (48-year-old man): compared with baseline (31.74 cc), the submental fat volume decreased to 24.59 cc at 1 month after treatment and 24.12 cc at 2 months after treatment. (B) S24 (39-year-old man): compared with baseline (18.98 cc), the submental fat volume decreased to 15.10 cc at 1 month after treatment and 11.43 cc at 2 months after treatment.

burns, scarring, and nerve damage.¹⁵ Cryolipolysis is a noninvasive technique that selectively induces apoptosis of adipocytes by using the high sensitivity of adipose tissue to cold. Its disadvantages include a long treatment duration of 45 to 60 minutes and common immediate posttreatment side effects such as erythema, edema, and numbness due to an inflammatory reaction within adipose tissue.^{16,17} Deoxycholic acid, an injectable product for chemical lipolysis, also carries significant side effects, such as frequent complications like pain, erythema, edema, and induration due to local tissue response, and further requires multiple treatments across numerous weeks.^{10,18}

The most recent exciting technologies to minimize recovery time are RF and HIFU; both are noninvasive contouring devices that are placed over the epidermis and emit RF or ultrasonic energy that preferentially heats fat more than other tissue types. Compared with other treatment options for reducing submental fat, these energy devices have an advantage in downtime and safety profiles after noninvasive procedures. Previous studies using monopolar RF or HIFU for the treatment of submental fat demonstrated significant clinical improvements in fat reduction with reasonable safety profiles.^{19,20} These studies also provided objective outcome data that quantified changes in submental fat through ultrasound measurement and 3D image analysis. One study with 2 treatments using an RF device reported that the mean thickness of submental fat decreased by 9.7% and 10.5% at 1- and 6-month follow-up compared with pretreatment, whereas another study with one treatment using a HIFU device reported that the mean surface area of submental fat decreased by 7.7% at 2-month follow-up. Notably, although the protocol and outcome measurements were heterogeneous, the results of the present study showed the most dramatic improvement compared with the quantitative evaluations of the 2 aforementioned studies, with a 19.72% decrease in the quantitative volume change of the submental fat at 2 months after a single treatment.

In the present study, the authors used a novel fractional RF device with micro-insulated needles to treat excess submental fat. This needle RF system has a fine, linear needle tip that can overcome the limitations of the contour of existing monopolar RF or HIFU applicators when applied to small areas. This device can effectively reduce fat volume by selectively contacting an array of 3 micro-insulated needles to the targeted area, the subcutaneous fat, at a controlled depth. A previous study evaluating the thickness of the lower facial skin and soft tissues using ultrasound examination in 200 healthy Koreans reported that the average thickness of the skin and superficial fat of the central neck was 1.59 ± 0.40 mm and 4.18 ± 1.22 mm, respectively.²¹ Therefore, a total length of 4-mm microneedles with proximal insulation of 2 mm can selectively treat superficial preplatysmal fat while protecting the epidermis from thermal damage. In addition, the unaffected areas between the 3 microneedles accelerated wound healing by maintaining skin integrity and minimizing the recovery time and side effects. Although not performed in this study, ultrasound may be helpful to corroborate

submental fat reduction and detect correlating tissue changes that underpin the submental contour improvement. However, as in the previous study in which the monopolar RF applied to the skin was conducted along the reticular fibers of the subcutaneous tissue producing a 3D contraction,¹⁹ outcomes of this study may also be related to both fat loss and skin tightening effect due to contraction of the dermis and reticular fiber network.

Most adverse events were mild, transient, and recovered without sequelae. An ulcer occurred in one patient at the beginning of the study, which might be related to the proficiency of the operator, and the resulting scar erythema improved after 3 consecutive laser treatments. If micro-insulated needles are inserted obliquely rather than perpendicular to the skin, the chance of burns may increase because of the shorter distance between the noninsulated distal needle tip and epidermis. Therefore, to prevent the occurrence of blisters or ulcers, it is necessary to pay attention to the angle at which the needle tips are inserted into the skin surface during the procedure.

This study has several limitations. First, this study had the relatively small sample size and the short-term follow-up period. Further studies are needed to determine whether submental fat reduction for more than 6 months can be maintained, and the patient characteristics that determine treatment efficacy need to be investigated. Additionally, this study included only Asian patients and limited age groups. According to ethnicity and age, the effects of RF energy on the skin and dermis and the clinical outcomes could be different.

In conclusion, the micro-insulated needle RF device can effectively reduce submental fat, with tolerable safety profiles. This minimally invasive method maximizes efficacy by directly inserting the distal noninsulated part of the microneedle into the depth of the fat deposit and minimizes downtime and side effects by preserving the epidermis resulting from the unaffected area between a row of microneedles and the proximal insulation. Thus, the authors were able to demonstrate significant clinical improvement and volume reduction of submental fat with fewer side effects with one treatment session using RF.

Author Contributions

Drs Kim and C.-H. Huh had full access to all the data in the study and take responsibility for the integrity of the data and the accuracy of the data analysis. Concept and design: J.-W. Shin, J.-I. Na, and C.-H. Huh. Acquisition, analysis, or interpretation of data: All authors. Drafting of the manuscript: B.R. Kim, M. Kim, and J.W. Kim. Critical revision of the manuscript for important intellectual content: All authors. Statistical analysis: B.R. Kim. Obtained funding: C.-H. Huh. Administrative, technical, or material support: M. Kim and J.W. Kim. Supervision: J.-W. Shin, J.-I. Na, and Huh.

Acknowledgments

The patients in this article have given written informed consent to publication of their case details.

References

1. Vazirnia A, Braz A, Fabi SG. Nonsurgical jawline rejuvenation using injectable fillers. *J Cosmet Dermatol* 2020;19:1940–7.
2. Coleman SR, Grover R. The anatomy of the aging face: volume loss and changes in 3-dimensional topography. *Aesthet Surg J* 2006;26:S4–9.
3. Thomas WW, Bloom JD. Neck contouring and treatment of submental adiposity. *J Drugs Dermatol* 2017;16:54–7.
4. Schlessinger J, Weiss SR, Jewell M, Narurkar V, et al. Perceptions and practices in submental fat treatment: a survey of physicians and patients. *Skinned* 2013;11:27–31.
5. Dong J, Amir Y, Goldenberg G. Advances in minimally invasive and noninvasive treatments for submental fat. *Cutis* 2017;99:20–3.
6. McDaniel D, Fritz K, Machovcova A, Bernardy J. A focused monopolar radiofrequency causes apoptosis: a porcine model. *J Drugs Dermatol* 2014;13:1336–40.
7. Tan MG, Jo CE, Chapas A, Khetarpal S, et al. Radiofrequency microneedling: a comprehensive and critical review. *Dermatol Surg* 2021;47:755–61.
8. Kleidona IA, Karypidis D, Lowe N, Myers S, et al. Fractional radiofrequency in the treatment of skin aging: an evidence-based treatment protocol. *J Cosmet Laser Ther* 2020;22:9–25.
9. Shin JW, Park JT, Chae JB, Choi JY, et al. The efficacy of micro-insulated needle radiofrequency system for the treatment of lower eyelid fat bulging. *JDDG* 2019;17:149–56.
10. Paik SH, Jung JM, Jung CJ, Yang HJ, et al. A randomized, double-blind, multi-center, placebo-controlled, phase 2 clinical trial to evaluate the efficacy and safety of DWJ211 in the treatment of moderate to severe submental fat. *Dermatol Ther* 2022;35:e15373. doi: 10.1111/dth.15373.
11. De Stefani A, Barone M, Hatami Alamdari S, Barjami A, et al. Validation of Vectra 3D imaging systems: a review. *Int J Environ Res Public Health* 2022;19:8820.
12. Lam KWP. A retrospective study on treatment of moderate cervicofacial laxity with subdermal monopolar radiofrequency with real-time monitoring. *J Cosmet Med* 2018;2:109–14.
13. Valizadeh N, Jalaly NY, Zarghampour M, Barikbin B, et al. Evaluation of safety and efficacy of 980-nm diode laser-assisted lipolysis versus traditional liposuction for submental rejuvenation: a randomized clinical trial. *J Cosmet Laser Ther* 2016;18:41–5.
14. Keramidis E, Rodopoulou S. Radiofrequency-assisted liposuction for neck and lower face adipodermal remodeling and contouring. *Plast Reconstr Surg - Glob Open* 2016;4:e850. doi: 10.1097/GOX.0000000000000809.
15. Katz B, McBean J. Laser-assisted lipolysis: a report on complications. *J Cosmet Laser Ther* 2008;10:231–3.
16. Bernstein EF, Bloom JD. Safety and efficacy of bilateral submental cryolipolysis with quantified 3-dimensional imaging of fat reduction and skin tightening. *JAMA Facial Plast Surg* 2017;19:350–7.
17. Kilmer SL, Burns AJ, Zelickson BD. Safety and efficacy of cryolipolysis for non-invasive reduction of submental fat. *Lasers Surg Med* 2016;48:3–13.
18. Goodman GJ, Spelman LJ, Lowe N, Bowen B. Randomized, placebo-controlled phase 1/2 study to determine the appropriate ATX-101 concentration for reduction of submental fat. *Dermatol Surg* 2021;47:1065–70.
19. Park JH, Kim JI, Park HJ, Kim WS. Evaluation of safety and efficacy of noninvasive radiofrequency technology for submental rejuvenation. *Lasers Med Sci* 2016;31:1599–605.
20. Kwon HH, Yang SH, Choi M, Jung JY, et al. Tightening and reduction of unwanted submental fat using triple-layer high-intensity focused ultrasound: clinical and 3-dimensional imaging analysis. *Dermatol Surg* 2021;47:1595–600.
21. Kwon SH, Ahn GY, Lew BL, Shin JW, et al. Clinical implication of the regional thickness of the lower facial skin, superficial fat, and superficial musculoaponeurotic system on high-intensity focused ultrasound treatment. *Dermatol Surg* 2022;48:527–31.